

Geo. Barton.
A. C. U.

Shape = Circular - biconcave disks.

Oxygen red marrow of bone

water 50% or over.

Comp } Haemoglobin &

Mineral matters.

Function carry oxygen

Shape = irregular

Size = large than a red and not only 1 to 30 red.

Oxygen = in lymph glands.

Function = destroys foreign substances.

Proteids
Oily and fatty matters

Serum } Sugar and common salt

carbonate of soda

And waste matter from various tissues.

Use = Coagulates the blood.

Blood < $\frac{1}{13}$ of weight of Body.

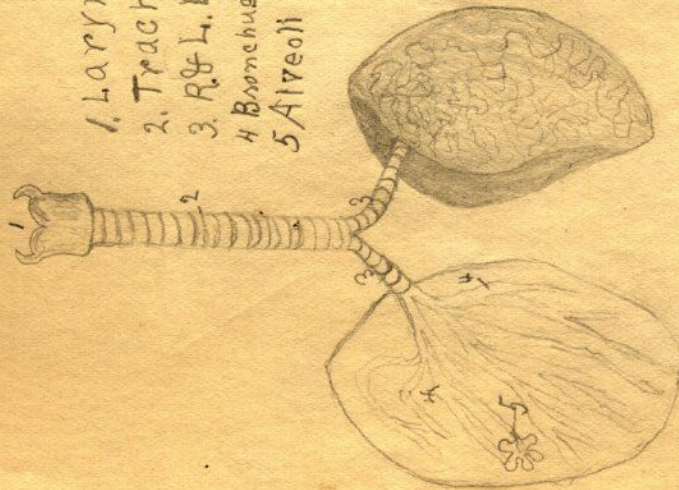
Corpuscles

Red

Plasma

Fibrin

1. Larynx
2. Trachea
3. R. & L. Bronchus
4. Bronchus Tubes
5. Alveoli



Ciliated-cell
Called Cilia



Circulatory Organs



1. Aorta
2. Coronary Arteries
3. Common carotid
4. Subclavian
5. Vertebral Artery
6. Axillary "
7. Brachial "
8. Thoracic "
9. Radial & Ulna
10. Abdominal
11. COELIAC AXIS
12. UPPER & LOWER mesenteric
13. Renal Arteries
14. Common Iliac Arteries
15. Femoral "
16. Popliteal Artery
17. Peroneal & tibial

Arteries

4 Stomach

Organs Muscles { Churns & mixes food

Stands Racemose

Tubular

Compound Racemose

Hel. { Methyligen White
Disolves Carbonate of Ph & of lime.

Salivary Juice

Repeating Changes
Proteids to Peptones
Remain { Coagulates Milk

Organic { mucus
& water

Same principle
comes from & chyme.

Salivary

Amplifier

Starch to sugar
Proteids to peptones

Stomach Pancreas

Trypsin
Steapsin
Emulsion

Breaks down
changes sugar

fat
oil
protein
fat.

5 Intestines

1 Prehension
lips
Teeth

Tongue
cheeks
lips

2 Mastication
Glands

Parotid
Sublingual
Submaxillary

Digestion

3 Deglutition
Tongue
Trices
Soft Palate
Epiglottis
Pharynx
Oesophagus

Secretion - Saliva (alkaline)

Moistens food
Dissolves Salt & Sugar
Amylin = Starch to Sugar

4 Stomach { Opening { Cardiac Orifice
 { Pyloric Orifice
 { Stomach { Gastric Glands

Small { Duodenum
 { Jejunum
 { Ileum

Intestines { Ileo caecal Valve, where the two meet.

Large { Caecum { Ascending Colon
 { Colon { Transverse "
 { Sigmoid "
 { Rectum { descending "

Gr. Canal

The Elementary Canal

1 Mouth

Lips
Cheeks
Tongue
Circumvolute Papillae
Fungiform
Filiform

Palate { Hard & Soft

Milk (20) 2 Jm, 1 C, 2 Mm
Perman (32) 2 Jm, 1 C, 2 Bp, 3 Mo.

Teeth { Dentic
Structure { ^{ent} crown
 { neck
 { Frond
 { Gms { Pulp cavity
 { Dentine
 { Enamel
 { Cement

Pillar of Faucis
Glands { Parotid
 Sublingual
 Submandibular

2 Pharynx or throat cavity

3 Oesophagus or gullet

Waters Standard Diet

Proteins Fat Carbohydrates

4.5 g. 4.9 17.5 g.

Pro. in cheese Cheese.
 $4.5 \div 31\% = 14.5$ g. required to furnish one man a day.

Pro. Fat Carb.

4.5 4. 17.5

Peas to furnish Carbohydrates
Carb. in peas
 $17.5 \div 55\% = 24.5$ g. required to furnish one man a day.

Good butter to furnish fat

fat in butter
 $4. \div 80\% = 4.9$ g. required to furnish one man a day.

Lean meat to furnish Proteins

Pro. in lean meat
 $4.5 \div 20\% = 22.5$ g. a day.

The Appendicular
skeleton

The pectoral girdle

- Clavicle 1
- Scapula 1
- Upper limb {
 - Humerus 1
 - Radius 1
 - Ulna 1
 - Carpals 8
 - Metacarpals
 - Phalanges 14

Os Innominatum 2

The pelvic girdle

- Lower limb {
 - Femur 1
 - Tibia 1
 - Fibula 1
 - Patella 1
 - Tarsals 7
 - Metatarsals 5
 - Phalanges 14

The bony skeleton

Cranial skeleton

The skull

Cranium

- Occipital 1
- Frontal 1
- Parietal 2
- Temporal 2
- Sphenoid 1
- Ethmoid 1

Face

- Mandible 1
- Zygomer 1
- Maxillae 2
- Palate 2
- Molar 2
- Nasal 2
- Lacrimal 2
- Inferior turbinate

Vertebral Column ^{separated}
bones


- Hyoid
- Sternum
- Ribs

The Appendicular skeleton

The pectoral arch or Girdle

The pelvic arch or Girdle

Chemical Composition of the body.



Zoology.

Physiology - treats of the properties & action of the body of the use or function of its parts, and of the manner of their workings.

Anatomy - treats of the form and structure of the parts of the body and deals with organs and parts of organs.

Histology - treats of the minute structure of the parts of the body deals with cells & tissues.

Hygiene - treats of the body in health and of the condition which promotes health.

Cell A cell is a mass of protoplasm containing nucleus.

Cells make tissues, tissues make organs. Organs make body.

Man is a vertebrate animal because his body presents dorsal and ventral cavities separated from one another by a hard partition, the back bone.

Man belongs to that subdivision of vertebrates known as Mammalia (1) because his body is covered by hair (2) because of the presence of mammary glands (3) because the ventral cavity is completely separated by the diaphragm into Thorax and abdomen.

Right Tibia

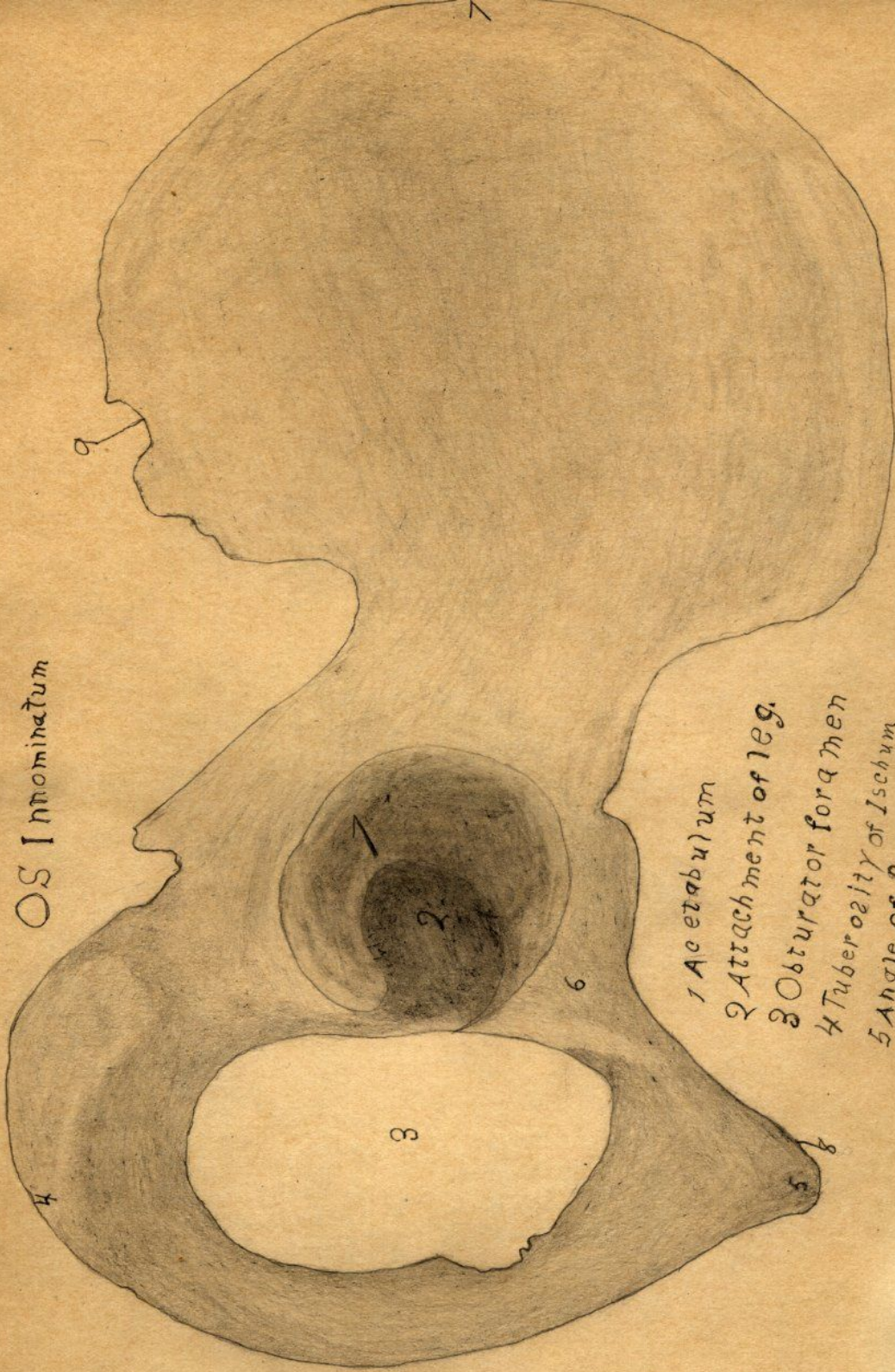
Articulates with
Astragalus

Articulates with
Fidula

Articulates
with Femur

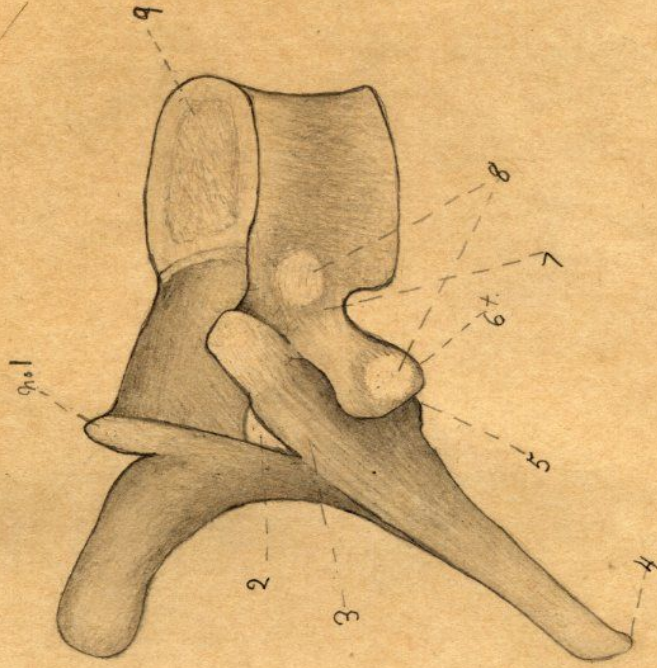


OS Innominatum



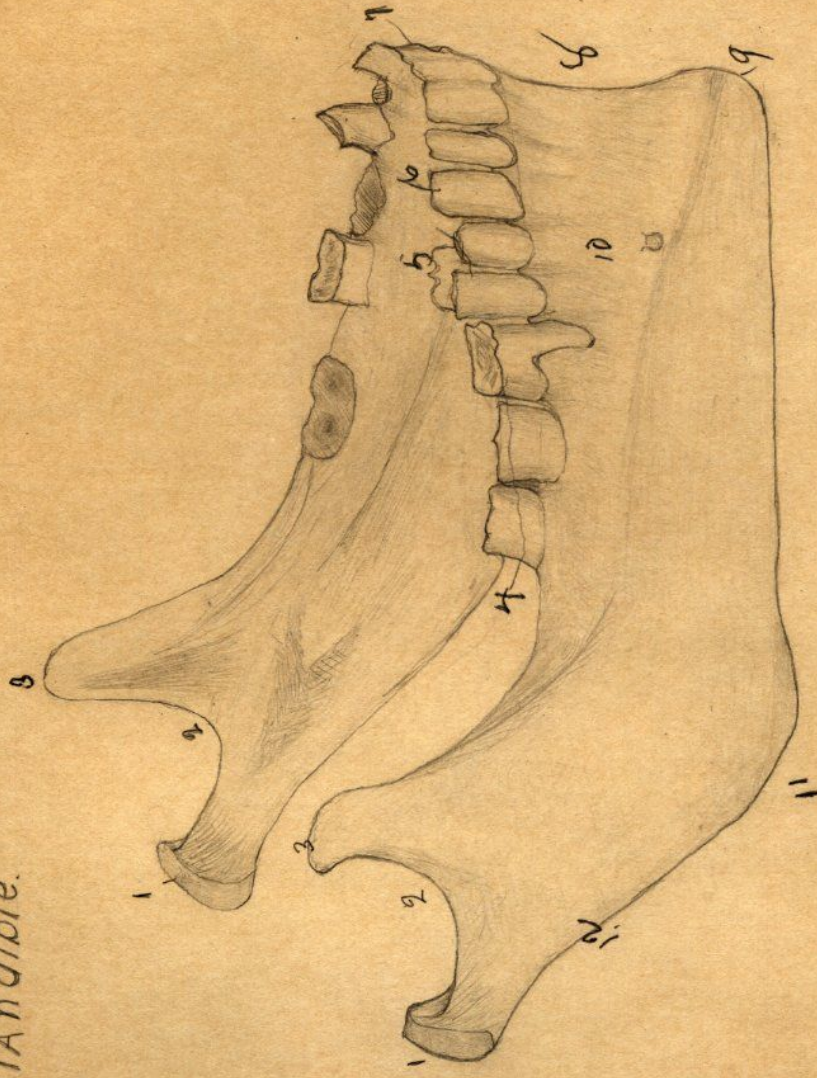
- 1 Acetabulum
- 2 Attachment of leg.
- 3 Obturator foramen
- 4 Tuberosity of Ischium
- 5 Angle of Pubes
- 6 Body of Pubes
- 7 Crest of Ilium
- 8 Articular surface
- 9 Lesser sciatic foramen

Fifth Dorsal vertebra



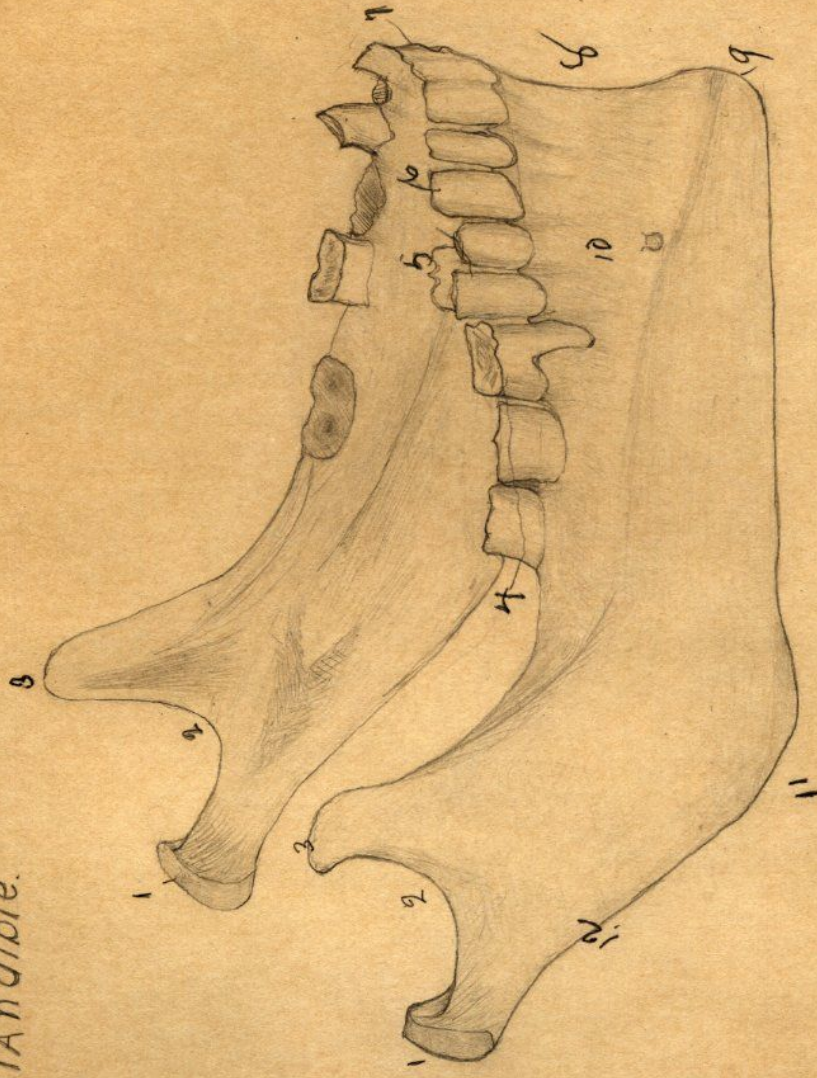
- 1 Ant Articular Process
- 2 Neural Canal
- 3 Neural Arch
- 4 Spinous Process
- 5 Posterior Art process
- 6 Transverse Process
- 7 Stalk or pedicle
- 8 Rib Articulations
- 9 Centrum or body

Mandible.



- 1. Condyles
- 2. Sigmoid process
- 3. Coronoid
- 4. Molars
- 5. Bicuspids
- 6. Canine
- 7. Incisor
- 8. Symphysis
- 9. Mental process
- 10. Body
- 11. Angle

Mandible.



- 1. Condyles
- 2. Sigmoid process
- 3. Coronoid
- 4. Molars
- 5. Bicuspids
- 6. Canine
- 7. Incisor
- 8. Symphysis
- 9. Mental process
- 10. Body
- 11. Angle

Femur

1 Depressions For ligamentum teres

2 Head

3 Articulates with Acetabulum

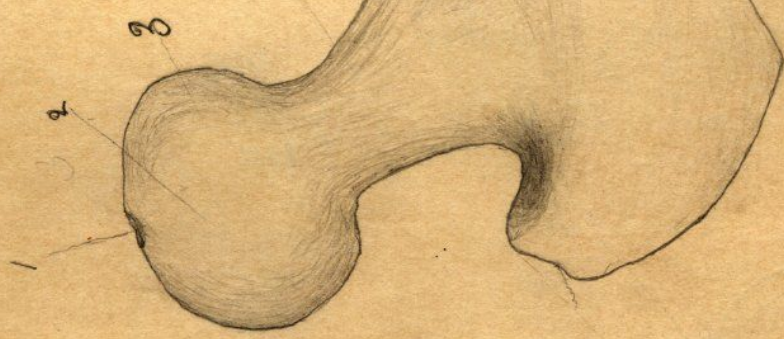4 Neck

5 Great Trochanter

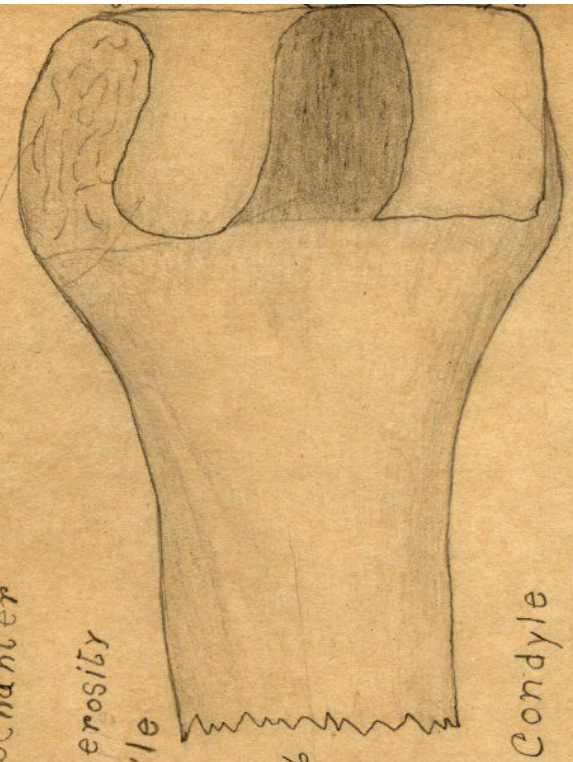
6 Shaft

7 Outer Tuberosity

8 " Condyle



"



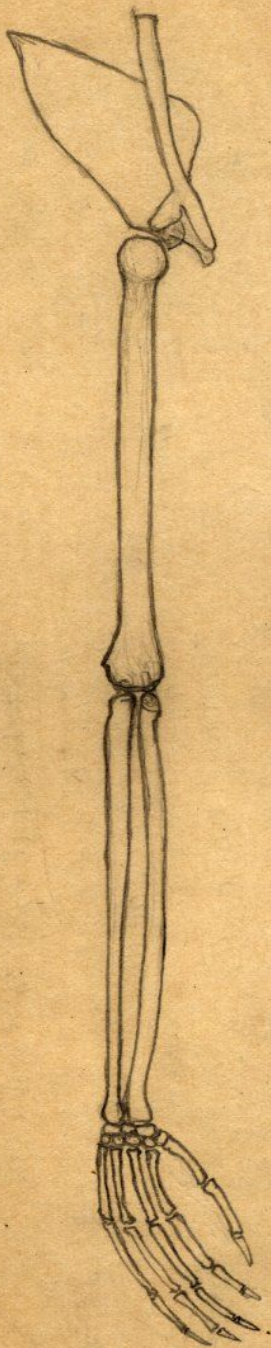
9 Inner Condyle

10 Articulates with Patella

11 Inner Tuberosity

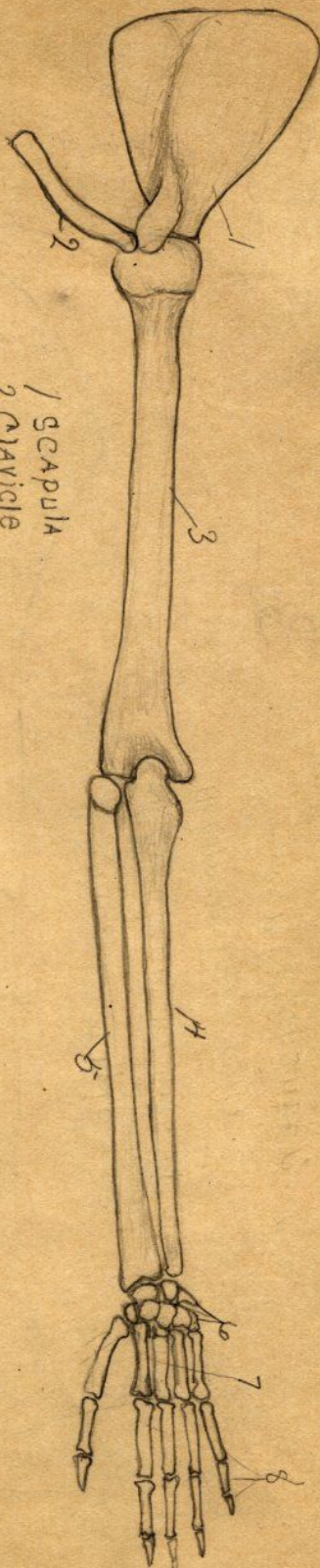
12 Lesser Trochanter

Monkey 2

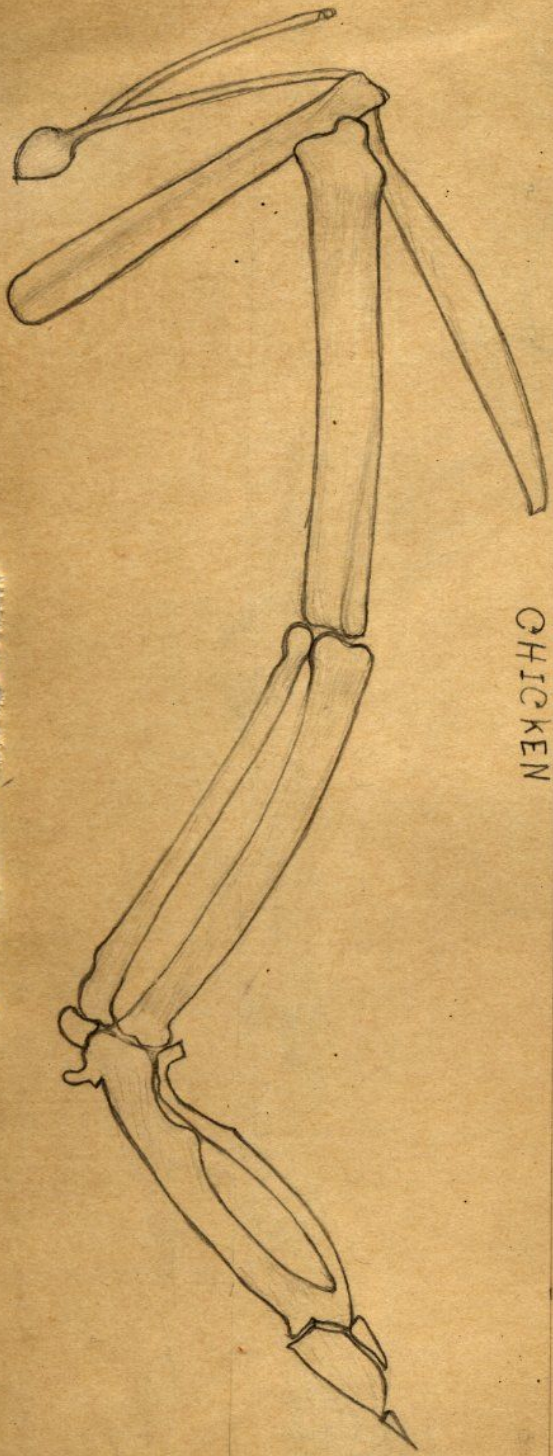


MONKEY

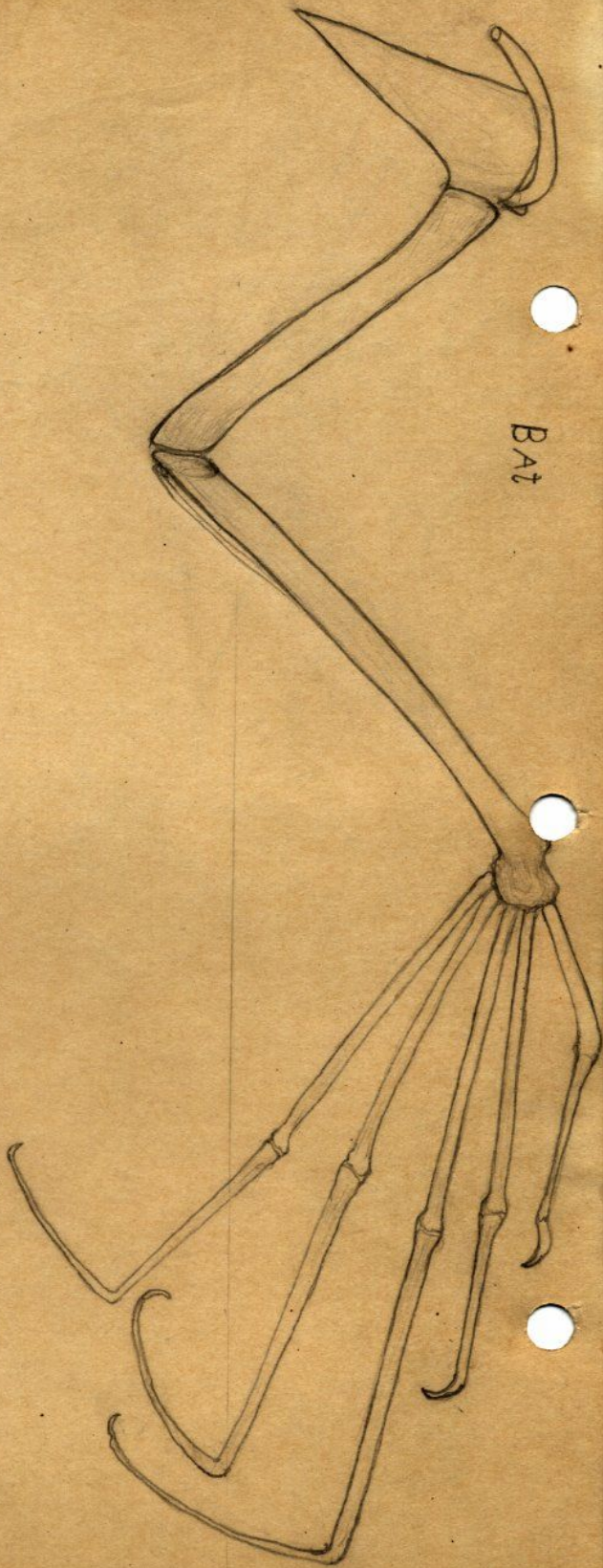
MAN



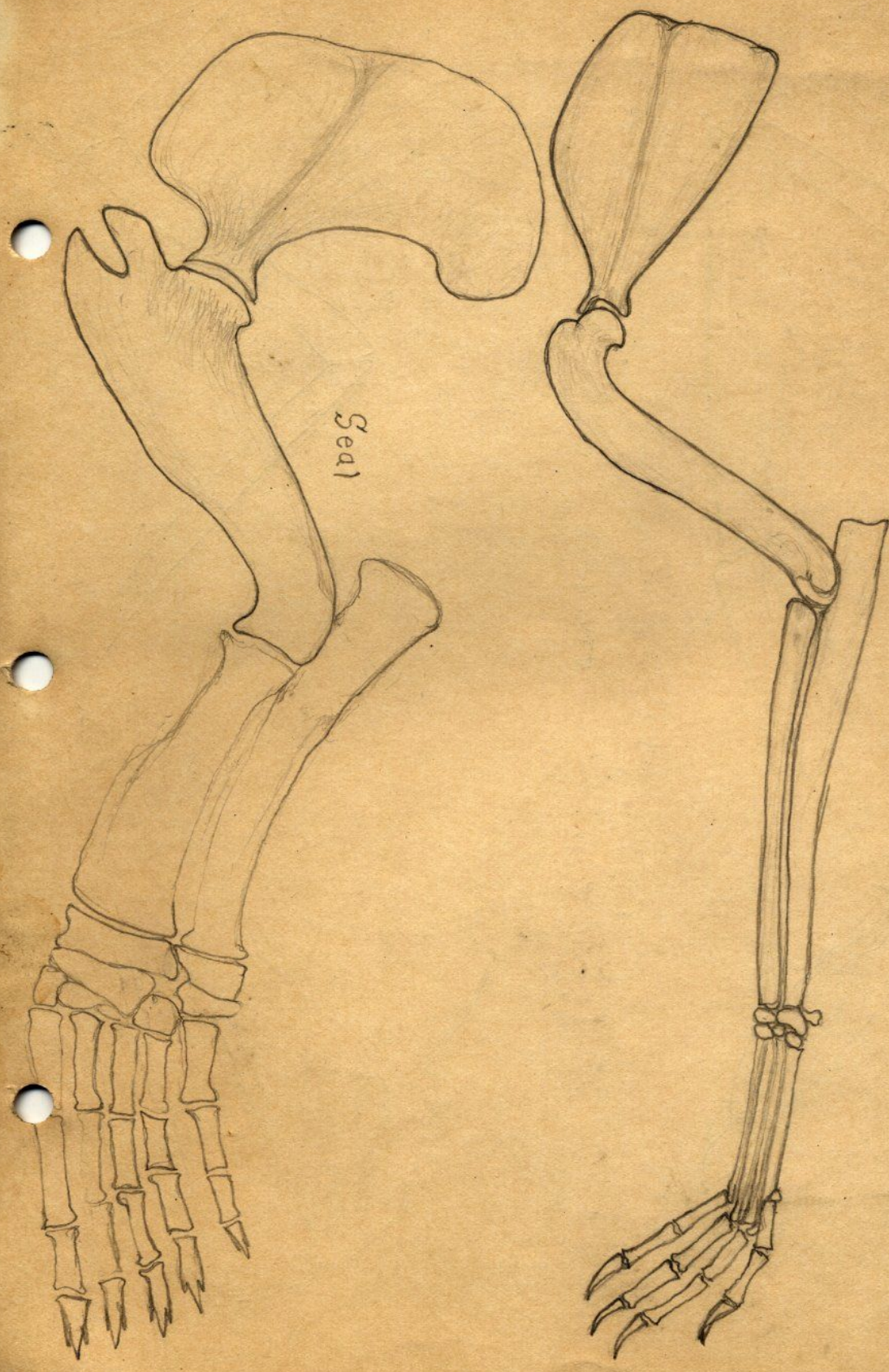
- 1 SCAPULA
- 2 CLAVICLE
- 3 HUMERUS
- 4 ULNA
- 5 RADIUS
- 6 CARPALS
- 7 METACARPALS
- 8 PHALANGES



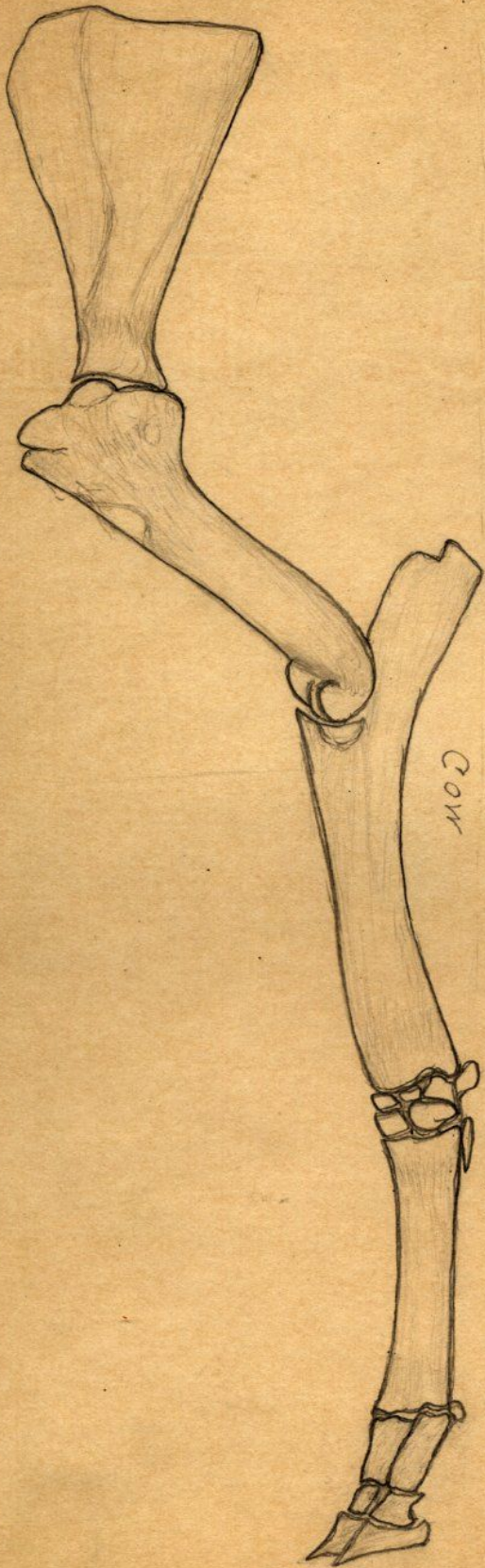
CHICKEN



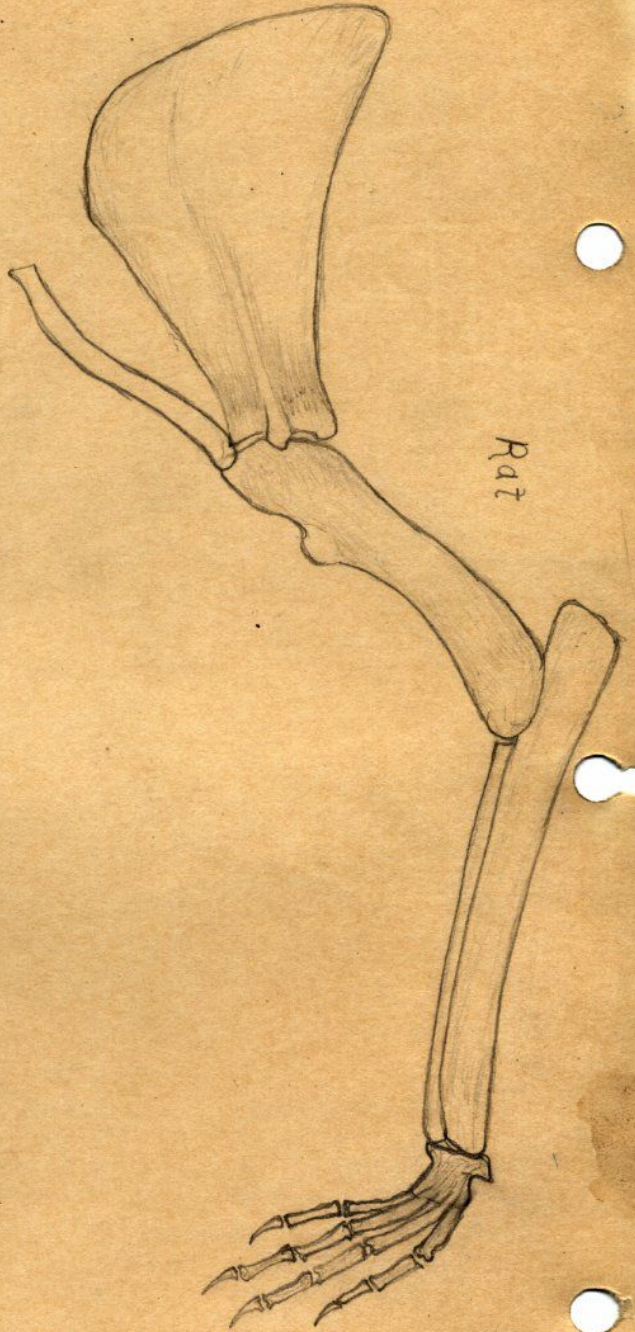
BAT



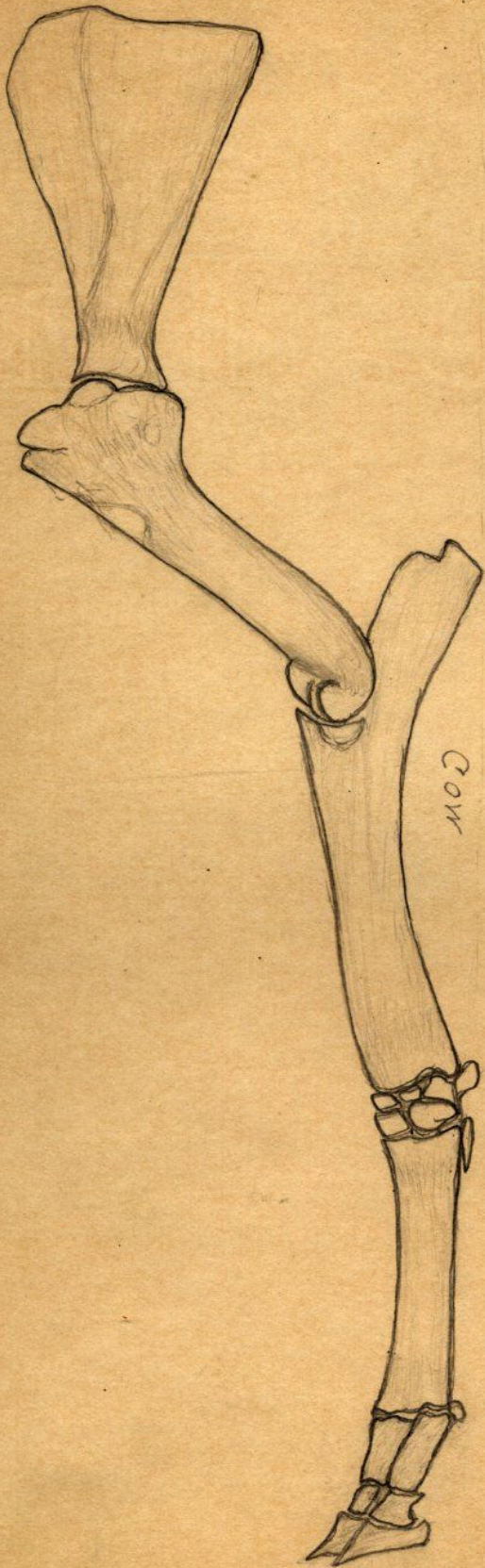
Seal



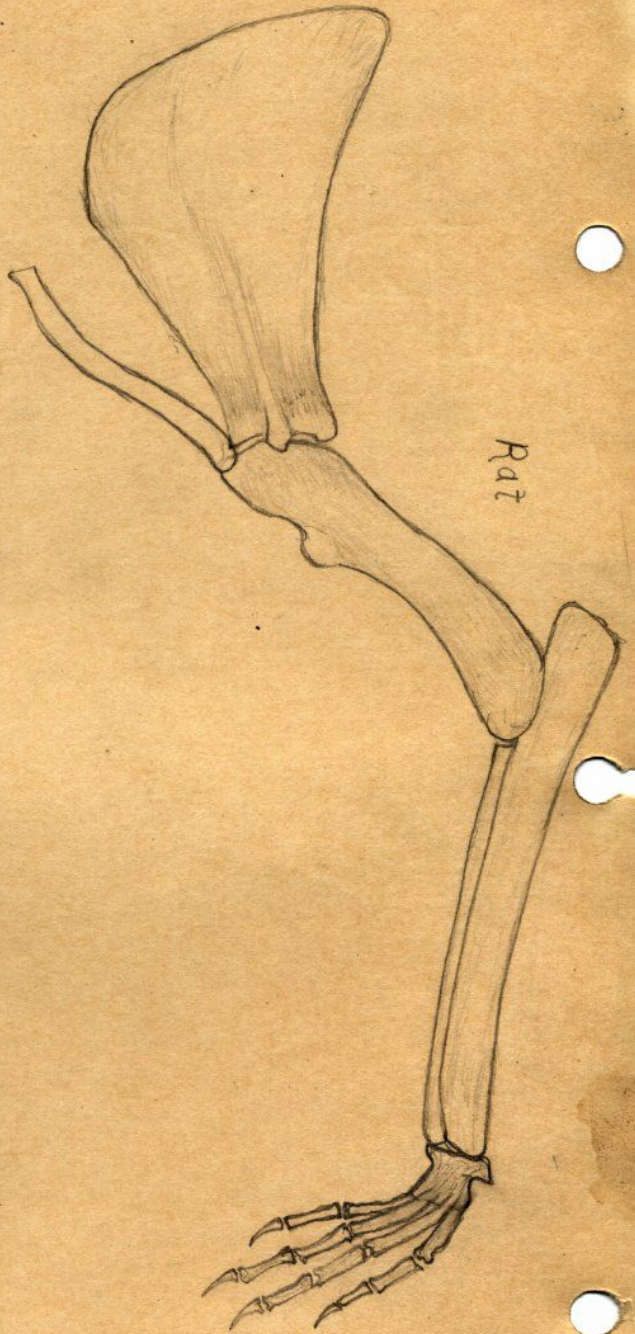
Cow



Rat



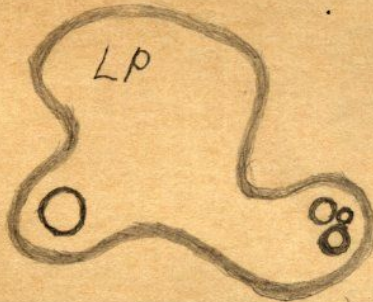
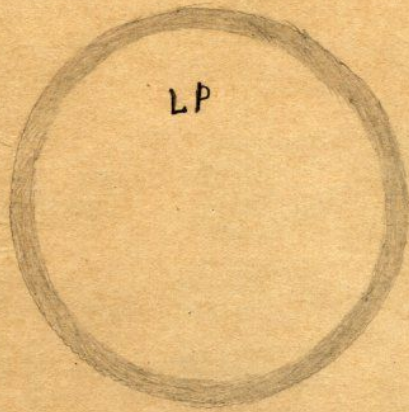
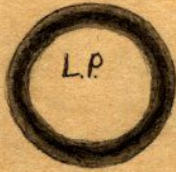
Cow



Rat

Air bubbles

L.P.



Blood corpuscles

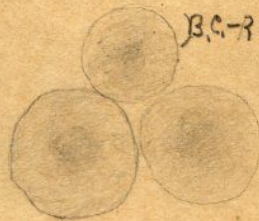
Cell




Cells



B.C. - Red flat



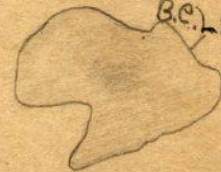B.C. - Red



B.C. - Light

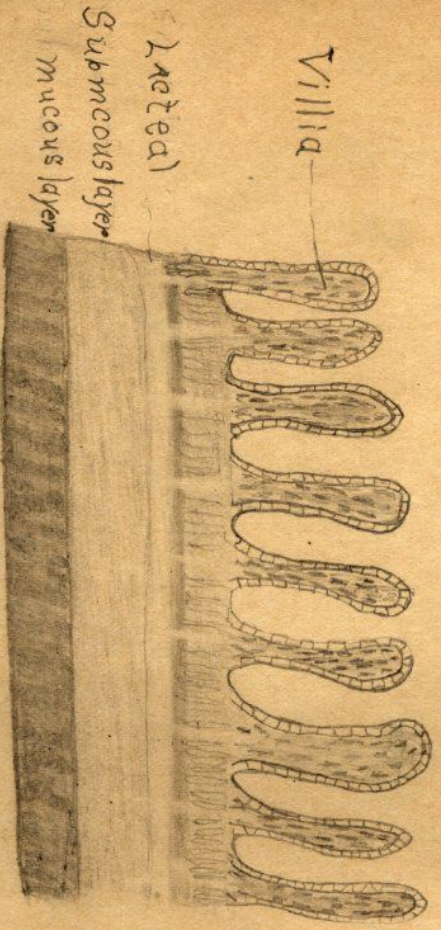


B.C. - Light



Sec. of Small Intestine
of mink cat

L.P.




HP

Sec. of Stomach

Point of mucus

L.P.



Sec. of Oesophagus

L.P.



Epithelium

Mucus


Sub. mucos

Long muscles

Round "

Mixed "


Tongue A.P.



Straited muscles

Tongue

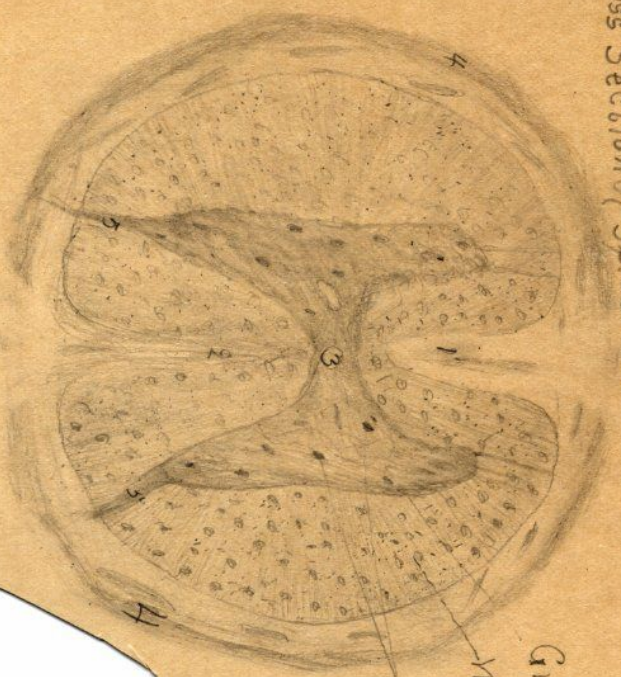
L.P.



Papillae

ends of muscles

Cross Section of Spinal Cord

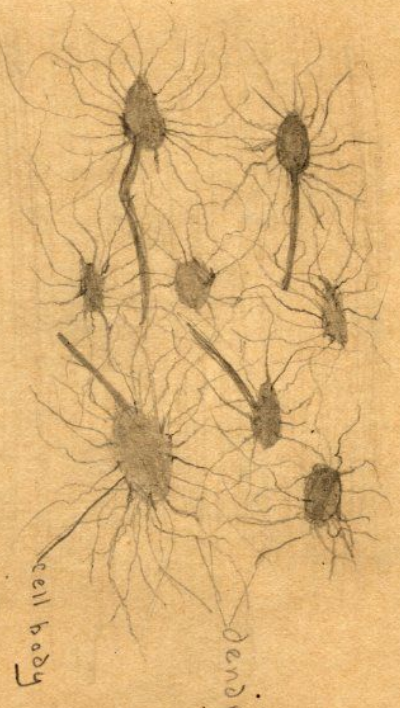


- 1 Anterior fissure
- 2 Posterior "
- 3 Central canal
- 4 Pia mater
- 5 Posterior Roots

L.P.

Gray Matter
 White "
 Nerve Cells

H.P. Nerve Cells of Brain



cell body
 dendrites

Boone
Cross Section

